

Chest Procedures

Key Teaching Objectives

Each candidate should receive practical instruction on the following:

1. Needle thoracocentesis
2. Chest drain insertion

If time permits a discussion on the following should occur:

3. Pericardiocentesis

During the course of this station the indications for and complications of each of the manoeuvres should be revised.

Equipment Required

Chest:

Plastic thorax models x 2 (Paediatric sizes)

Sleek tape to be applied directly to the outside of the ribs to mimic the pleura

Limbs & Things Skin Pad cut to shape x2. One for each hemi-thorax with each group using a single fresh hemi-thorax

Printed instructions for assembling the skeleton models to guide assembly - available online under APLS Course Materials

Small BP Scalpel Handles x2

Scalpel blades Size 11 (Boxes) x2

Scissors

Curved Haemostats x4

Clamps x2

Large Hard Suture needles x2

Cotton (black 30m) x2



Spinal needles 16g x4 ???

5 - 20ml syringes x2 of each depending upon the size of the skeleton being used

IV cannulas x2 of appropriate size for the skeleton sizes being used

Chest drains of various sizes appropriate for the size of plastic thorax being used

Laminated cards re: IC Catheters and Finger thoracostomy

Intercostal catheters		Finger Thoracostomy																					
Requirements for safe insertion <ul style="list-style-type: none"> • Familiarity with the equipment available in your institution • Developing the skill through training and practice • Selecting the right patient 		<ul style="list-style-type: none"> • Invasive procedure used to decompress a possible tension pneumothorax urgently (as an alternative to needle thoracocentesis) • Involves rapid sharp incision down to rib, 5th or 4th IC space, anterior to mid-axillary line, and blunt penetration of the rib space and pleura by a gloved finger. • Withdrawal of the finger then allows rapid release of a tension pneumothorax or on occasion a tension haemothorax. 																					
<table border="1"> <thead> <tr> <th>Large bore ICC</th> <th>Small bore ICC</th> </tr> </thead> <tbody> <tr> <td>Most common type used in children</td> <td>Most common catheter used in neonates</td> </tr> <tr> <td>Considered more effective in critical trauma – for rapid air and blood evacuation</td> <td>Should be considered in stable trauma - can drain both air and blood</td> </tr> <tr> <td>Open surgical approach</td> <td>Seldinger technique</td> </tr> <tr> <td>More invasive and painful</td> <td>Less invasive and well tolerated</td> </tr> <tr> <td>More scarring</td> <td>Less scarring</td> </tr> </tbody> </table>	Large bore ICC	Small bore ICC	Most common type used in children	Most common catheter used in neonates	Considered more effective in critical trauma – for rapid air and blood evacuation	Should be considered in stable trauma - can drain both air and blood	Open surgical approach	Seldinger technique	More invasive and painful	Less invasive and well tolerated	More scarring	Less scarring		<table border="1"> <thead> <tr> <th>Indications</th> <th>Cautions and Considerations</th> </tr> </thead> <tbody> <tr> <td>High suspicion of tension haemo/pneumothorax, with critical clinical instability</td> <td>Used inappropriately in spontaneously breathing patient causes 'open pneumothorax' and may collapse lung</td> </tr> <tr> <td>As part of Traumatic Cardiac Arrest (TCA) where tension haemo/pneumothorax may be responsible</td> <td>Not as management for any pneumothorax, and should always have ICC placed after procedure</td> </tr> <tr> <td>For urgent intervention in a deteriorating ventilated patient where tension haemo/pneumothorax may be the cause</td> <td>Likely more effective in the school age child, and significantly more difficult and less appropriate in infants</td> </tr> </tbody> </table>	Indications	Cautions and Considerations	High suspicion of tension haemo/pneumothorax, with critical clinical instability	Used inappropriately in spontaneously breathing patient causes 'open pneumothorax' and may collapse lung	As part of Traumatic Cardiac Arrest (TCA) where tension haemo/pneumothorax may be responsible	Not as management for any pneumothorax, and should always have ICC placed after procedure	For urgent intervention in a deteriorating ventilated patient where tension haemo/pneumothorax may be the cause	Likely more effective in the school age child, and significantly more difficult and less appropriate in infants	
Large bore ICC	Small bore ICC																						
Most common type used in children	Most common catheter used in neonates																						
Considered more effective in critical trauma – for rapid air and blood evacuation	Should be considered in stable trauma - can drain both air and blood																						
Open surgical approach	Seldinger technique																						
More invasive and painful	Less invasive and well tolerated																						
More scarring	Less scarring																						
Indications	Cautions and Considerations																						
High suspicion of tension haemo/pneumothorax, with critical clinical instability	Used inappropriately in spontaneously breathing patient causes 'open pneumothorax' and may collapse lung																						
As part of Traumatic Cardiac Arrest (TCA) where tension haemo/pneumothorax may be responsible	Not as management for any pneumothorax, and should always have ICC placed after procedure																						
For urgent intervention in a deteriorating ventilated patient where tension haemo/pneumothorax may be the cause	Likely more effective in the school age child, and significantly more difficult and less appropriate in infants																						

Laminated card with QR code for videos from Tracey Merriman (landmarks and procedure)

Prep for Thoracic Skills

Landmarks (5 mins)

SCAN ME



<https://flowcode.com/b/OZPni3K08?fc=0>

Chest Tube Insertion (7 mins)

SCAN ME



• <https://flowcode.com/p/OZPnRaCvY?fc>

Environment

The room should be divided into two, one station should be set-up for needle thoracocentesis and another station for chest drain insertion. Instructors should also consider how they will demonstrate pericardiocentesis. Care should be taken to protect floor and tables. Each station will require one or two tables, which should be set-up in such a way as to allow free access on all sides.

Plan

Set

"During this session you are going to be taught how to carry out a needle thoracocentesis and insert a chest drain."

Dialogue

This station is taught using the 4-part technique described in the Preface to Practical Procedures. The following techniques should be taught:

Needle Thoracocentesis

1. Identify the second intercostal space in the midclavicular line on the side of the pneumothorax (the *opposite* side to the direction of tracheal deviation).
2. Swab the chest wall with surgical prep or an alcohol swab.
3. Attach the syringe to the cannula.
4. Insert the cannula into the chest wall, just above the rib below, aspirating all the time.
5. If air is aspirated remove the needle, leaving the plastic cannula in place.
6. Tape the cannula in place and proceed to chest drain insertion as soon as possible.

Chest Drain Insertion

1. Decide on the insertion site (usually the fifth intercostal space in the mid axillary line) on the side with the pneumothorax.
2. Swab the chest wall with surgical prep or an alcohol swab.
3. Use local anaesthetic if necessary.
4. Make a 2 - 3 cm skin incision along the line of the intercostal space, just above the rib below.
(A 2-3 cm long incision may be too big in a small infant. The incision size should reflect the size of the child and the size of the drain, but note that usually candidates make an incision that is too small.)
5. Bluntly dissect through the subcutaneous tissues just over the top of the rib below, and puncture the parietal pleura with the tip of the clamp.
6. Put a gloved finger into the incision and clear the path into the pleura if possible (Putting a gloved finger in the incision is only possible in larger children and should not be attempted if the operators finger is clearly too large for the space between the ribs).

7. Ensure that the stylet has been removed from the catheter. Advance the chest drain tube into the pleural space.
8. Ensure the tube is in the pleural space by listening for air movement, and by looking for fogging of the tube during expiration.
9. Connect the chest drain tube to an underwater seal or Heimlich valve.
10. Secure the drain in place with tape. In some circumstances suturing is appropriate but care should be taken to protect the breast tissue of girls and to minimise the size of the scar.
11. Obtain a chest X-Ray

Discussion of Pericardiocentesis

Where possible this should be performed under ultrasound guidance.

1. Swab the xiphoid and subxiphoid areas with surgical prep or an alcohol swab.
2. Use local anaesthetic if necessary.
3. Assess the patient for any significant mediastinal shift if possible.
4. Attach the syringe to the needle.
5. Puncture the skin 1 - 2 cm inferior to the left side of the xiphoid junction at a 45 degree angle.
6. Advance the needle towards the tip of the left scapula, aspirating all the time.
7. Watch the ECG monitor for signs of myocardial injury.
8. Once fluid is withdrawn aspirate as much as possible (unless it is possible to withdraw limitless amounts of blood in which case a ventricle has probably been entered).
9. If the procedure is successful, remove the needle leaving the cannula in the pericardial sac. Secure in place and seal with a 3-way tap. This allows later repeat aspirations should tamponade recur.

Finally

Advise candidates to familiarise themselves with the equipment and its location in their own institution for all these techniques on their return to their place of work.

Closure


Candidates should be given a formal opportunity to ask any questions, when these have been answered to the candidates' satisfaction, the session can be closed by repeating the procedures used.

Assessment Technique

A record of candidates' performance during the station should be kept for faculty reference

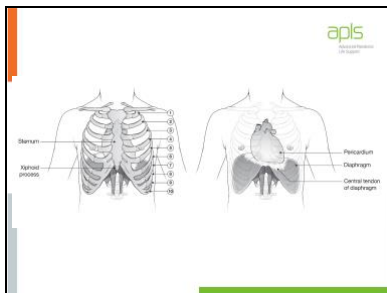
These slides are an optional resource to support recall from videos

Slide 1



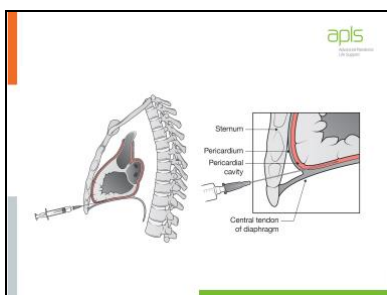
These slides are aimed at ensuring that our anatomical knowledge is correct and that we are teaching our candidates to do procedures in the right place. The techniques are not hard, but choosing the right anatomical landmarks is poorly done.

Slide 2



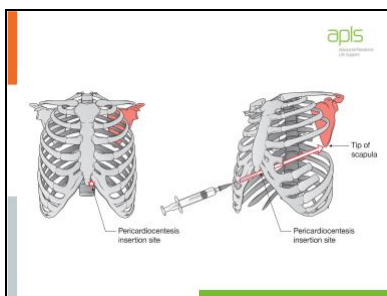
The central tendon of the diaphragm is attached to the back of the xiphisternum, and the fibrous pericardium is fused to this.

Slide 3



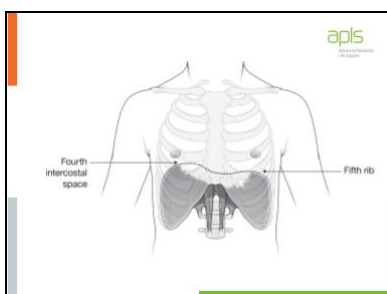
Remember that a pericardiocentesis needle is aiming to get into the narrow space between the pericardium and the myocardium, which even in the presence of a pericardial tamponade will not be wide.

Slide 4



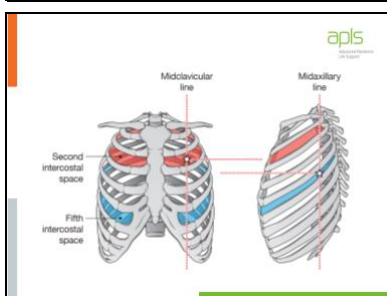
The needle is inserted to the left of the xiphisternum and is pointed to the tip (or inferior angle) of the scapula. This is NOT the shoulder, but rather the lowermost part of the scapula. The needle therefore pierces the diaphragm and pericardium and runs between the myocardium and pericardium. So when a patient is supine the needle is almost going directly backwards. Angling towards the shoulder will result in perforation of the heart.

Slide 5



The domes of the diaphragm in expiration sit at the 4th interspace on the right and the 5th rib on the left at the front of the chest. That means that chest tubes need to be inserted well above that level to get into the correct space away from the heart, mediastinum and major vessels.

Slide 6



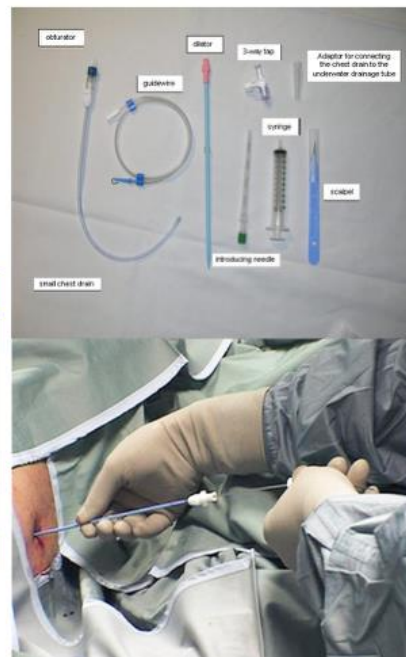Important anatomical points are that the ribs slope downwards so the level of the rib at the front of the chest is very different from the back. The second rib space (for needle thoracocentesis) allows access into a safe area within the thoracic cavity. It is almost at the same level as the 5th IC space in the mid-axillary line (for ICC insertion) as the intention is to get into the same safe area. Ideally an ICC in the 4th IC space would be ideal but it is hard to get that high in the axilla. A common mistake is to think the 2nd space MCL is too high, and the 5th space is too low which will lead to difficulty and risk of complication if performing a chest procedure (ICC or finger thoracostomy).

Intercostal catheters

Requirements for safe insertion

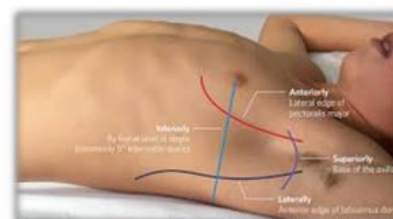
- Familiarity with the equipment available in your institution
- Developing the skill through training and practice
- Selecting the right patient

Large bore ICC	Small bore ICC
Most common type used in children	Most common catheter used in neonates
Considered more effective in critical trauma – for rapid air and blood evacuation	Should be considered in stable trauma - can drain both air and blood
Open surgical approach	Seldinger technique
More invasive and painful	Less invasive and well tolerated
More scarring	Less scarring



Finger Thoracostomy

- Invasive procedure used to **decompress a possible tension pneumothorax** urgently (as an alternative to needle thoracocentesis)
- Involves **rapid sharp incision down to rib, 5th or 4th IC space**, anterior to mid-axillary line, and **blunt penetration of the rib space and pleura** by a gloved finger.
- **Withdrawal of the finger then allows rapid release** of a tension pneumothorax or on occasion a tension haemothorax



Indications	Cautions and Considerations
High suspicion of tension haemo/pneumothorax, with critical clinical instability	Used inappropriately in spontaneously breathing patient causes 'open pneumothorax' and may collapse lung
As part of Traumatic Cardiac Arrest (TCA) where tension haemo/pneumothorax may be responsible	Not as management for any pneumothorax, and should always have ICC placed after procedure
For urgent intervention in a deteriorating ventilated patient where tension haemo/pneumothorax may be the cause	Likely more effective in the school age child, and significantly more difficult and less appropriate in infants

